



PATIENT

Angus Kennedy

PRESENTING CLINICAL SIGNS

History: Echocardiogram prior to anesthesia for dental prophylaxis. BP: 143,144, 147 mmHg.

SPECIES

Canine

ECHOCARDIOGRAM FINDINGS

2D, m-mode, color flow and Doppler imaging is available.

Left ventricle: The LV diameter is mildly increased with hyperdynamic function. LV wall thicknesses are normal.

Left atrium: The left atrium is moderately dilated.

Mitral valve: The mitral valve is diffusely thickened with mild prolapse into the left atrial lumen. Moderate eccentric mitral regurgitation with a normal velocity.

Aortic valve/Aorta: The aortic valve is normal in morphology and mobility. Normal aortic outflow velocity; laminar flow. Trace aortic insufficiency.

Right ventricle: Mild RV enlargement.

Right atrium: Mild RA enlargement.

Tricuspid valve: The tricuspid valve appears mildly thickened with septal prolapse and mild to moderate tricuspid regurgitation. Velocity consistent with early pulmonary hypertension.

Pulmonic valve/Pulmonary artery: The pulmonic valve is normal in morphology and mobility. No pulmonic insufficiency. Normal RVOT velocity; laminar flow.

Pericardium/other: No pericardial or pleural effusion noted. No obvious cardiac masses.

Heart rhythm: ECG reveals a sinus rhythm with an average HR of 90bpm.

BREED

Miniature Schnauzer

SEX

Male Neutered

AGE

11 years

WEIGHT

17.5lbs

2-Dimensional Measurements

Ao diam (cm)	1.4
LA diam (cm)	2.4
LA:Ao (Swe)	1.7
IVS thickness (cm)	0.6
LVID diastole (cm)	3.1
PW thickness (cm)	0.7
LVID systole (cm)	1.5
FS (%)	51

Doppler Measurements

PV Vmax (m/s)	0.9
AoV Vmax (m/s)	1.7
MR Vmax (m/s)	5.1
TR Vmax (m/s)	2.9
TR PG (mmHg)	34

INTERPRETED BY

Maggie Machen
Lamy, DVM
DACVIM (Cardiology)

IMAGING

PERFORMED BY

Pamela Harrigan,
RDCS

HOSPITAL NAME

Norfolk County
Veterinary Service

REFERRING VET

Dr. McCabe

INTERPRETATION OF THE FINDINGS

Chronic degenerative valve disease causing moderate mitral and mild to moderate tricuspid regurgitation. Moderate left atrial enlargement indicates there is relatively low risk for imminent complication, however risk for progression to spontaneous congestive heart failure in the future is elevated. Early pulmonary hypertension is noted, which should be monitored going forward. Finally, a small aortic leak is noted; however, the reported blood pressure is normal. No additional issues are identified.

Given LA dilation, Pimobendan is recommended as below. Assessment of progression in the future will help predict long term outcome, however prognosis is guarded at this stage (B2).

INVOICE

29500

DATE

3/9/23



PATIENT

Angus Kennedy

SPECIES

Canine

BREED

Miniature Schnauzer

SEX

Male Neutered

AGE

11 years

WEIGHT

17.5lbs

INTERPRETED BY

Maggie Machen
 Lamy, DVM
 DACVIM (Cardiology)

IMAGING PERFORMED BY

Pamela Harrigan,
 RDCS

HOSPITAL NAME

Norfolk County
 Veterinary Service

REFERRING VET

Dr. McCabe

INVOICE

29500

DATE

3/9/23

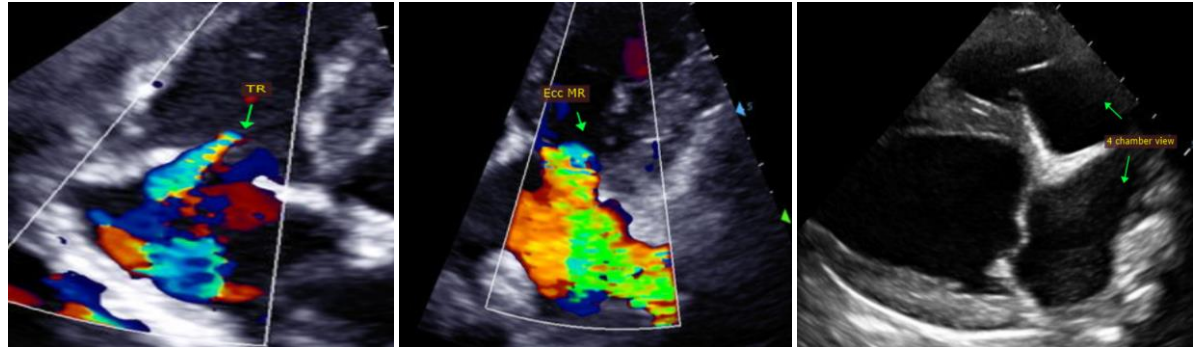
RECOMMENDATIONS

- Institute heart muscle support Pimobendan 0.3mg/kg PO q12h.
- Omega fatty acid supplementation and mild salt restriction may be of some long-term benefit.
- Once on Pimobendan for 3-5 days, anesthetic risk is considered mild if needed. Cardiac protective drug choices (opioid/benzodiazepine premedication, propofol or alfaxalone induction, isoflurane gas) are recommended. Pre-oxygenate for 5-10 minutes prior to induction. Monitor for arrhythmias, hypotension, and hypoxia both intra and post-operatively and intervene as necessary. Mild IV fluid restriction is recommended to avoid fluid overload. Avoid heart rate stimulating drugs such as atropine unless clinically indicated.
- Monitor for development of a cough, labored breathing, exercise intolerance or collapse episodes.

PLAN

- Recommend conservative monitoring with a recheck echocardiogram in 6 months, sooner if any development of clinical signs.

IMAGES



The information and recommendations provided are based on the images presented by the referring veterinarian. No evaluation can be communicated regarding pathology that was not visible in the image/video clips provided.

Thank you for this referral. This report was generated using transcription software, and minor dictation errors may be present. If the clinical or image interpretation does not parallel your findings or if I can be of any further assistance, please contact me.

Maggie Machen Lamy, DVM
 Diplomate of the American College of Veterinary Internal Medicine (Cardiology)
 info@sonopath.com

Echocardiogram performed by: Pamela Harrigan, RDCS
 Pet Animal Ultrasound Service (4paus.com)